

Comparison of Cardiac Size in Posteroanterior Chest X-Ray and Echocardiography

Agustining Rahayu¹, Bachtiar Murtala², Sri Asriyani², Andi Alfian Zainuddin³, Muzakkir⁴,
Nikmatia Latief²

¹Departement of Radiology, Faculty of Medicine, Hasanuddin University/Wahidin Sudirohusodo Hospital, Makassar

²Departement of Radiology, Faculty of Medicine, Hasanuddin University/Wahidin Sudirohusodo Hospital, Makassar

³Departement of Family Medicine and Public health, Faculty of Medicine, Hasanuddin University/
Wahidin Sudirohusodo Hospital, Makassar

⁴Departement of Cardiology, Faculty of Medicine, Hasanuddin University/Wahidin Sudirohusodo Hospital, Makassar

Email: dr.agustining@gmail.com

ABSTRACT

Cardiac size is important to determine the presence of cardiac enlargement caused by left ventricular enlargement or right ventricular enlargement. Although echocardiography is considered to be the gold standard for cardiac enlargement, its availability is limited, expensive and requires trained experts. The posteroanterior (PA) chest X-ray (CXR) is the most common imaging used as a reliable alternative. The aim of this study was to compare cardiac size using cardiothoracic ratio (CTR) and transverse left cardiothoracic ratio (TL-CTR) in PA chest X-ray and echocardiography. This cross-sectional study involved 88 inclusion sample, aged 20-60 years. On the basis of provisional clinical diagnosis, the patients were divided three groups, consist of: (i) Group with normal cardiac size, (ii) Group with left ventricular enlargement (LVE) dan (iii) Group with right ventricular enlargement (RVE). All patients underwent PA CXR and M-Mode echocardiography examinations. The results of the two modalities were compared. CTR and TL-CTR, transverse diameter (TD) and transverse left (TL) in PA chest X-ray showed a strong positive correlation with total ventricular dimension (TVD) and left ventricular internal dimension (LVID) in echocardiography. CTR, TL-CTR, TD and TL in the PA chest X-ray are very good indicators for TVD and LVID in echocardiography. Chest X-ray is a reliable alternative for the diagnosis of cardiomegaly/cardiac enlargement in the absence of echocardiography.

Keywords: Cardiomegaly, posteroanterior chest X-ray, M-mode echocardiography

ABSTRAK

Ukuran jantung adalah penting diketahui untuk mengidentifikasi adanya pembesaran jantung, baik yang disebabkan oleh pembesaran ventrikel kiri maupun pembesaran ventrikel kanan. Ekokardiografi dianggap sebagai golden standar untuk mendiagnosa pembesaran jantung, namun ketersediaannya terbatas, mahal serta memerlukan tenaga ahli terlatih. Foto dada posteroanterior (PA) adalah pemeriksaan radiologi yang paling sering dilakukan diharapkan dapat digunakan sebagai alternative yang dapat diandalkan. Tujuan dari penelitian ini adalah untuk membandingkan ukuran jantung dengan indikator rasio kardiotorak (CTR) dan rasio kardiotorak transversal kiri jantung (CTR-TL) pada pemeriksaan foto dada PA dan ekokardiografi. Penelitian *cross sectional* ini meliputi 88 sample inklusi, usia antara 20-60 tahun. Berdasar diagnose klinis, sample dibagi menjadi 3 grup, terdiri dari: (i) grup dengan ukuran jantung normal, (ii) grup mengalami pembesaran ventrikel kiri dan (iii) grup dengan pembesaran ventrikel kanan. Semua pasien menjalani pemeriksaan foto dada PA dan ekokardiografi *M-Mode*. Hasil pengukuran dari kedua modalitas tersebut kemudian dibandingkan. Dari hasil perbandingan didapatkan, CTR dan TL-CTR, diameter transversal (TD) dan diameter transversal kiri (TL) pada foto dada PA menunjukkan korelasi positif kuat dengan dimensi ventrikel total jantung (TVD) dan dimensi ventrikel kiri (LVID) pada ekokardiografi. Dari penelitian ini dapat disimpulkan bahwa foto dada PA merupakan alternative yang andal dalam mendiagnosa kardiomegali/pembesaran jantung tanpa adanya ekokardiografi

Kata kunci: Kardiomegali, foto dada Posteroanterior, ekokardiografi

1. Introduction

Cardiac size is very important in order to find cardiac enlargement due to left ventricular enlargement or right ventricular enlargement. Cardiac enlargement can be caused by several diseases such as hypertension, coronary heart disease, obesity, and heart valve disease. Currently, the prevalence of heart disease caused by hypertension, coronary heart disease, diabetes, obesity or heart valve disease tends to increase¹. Detection of cardiac enlargement should be done as early as possible so that it can be treated early before falling into severe state.

2D echocardiography is considered the gold standard for diagnosing cardiac enlargement^{2,3}. The advantages of echocardiography are its ability to display real-time cardiac space and function^{4,5}, it is not invasive, not affected by chest deformity and inspiration/expiration of patients, however it has some disadvantages such as costs, limited availability and very dependent on operator capability causing limited use of this tool⁶.

With some deficiencies in echocardiography, alternative radiological modalities that can be relied upon are needed in the hope of helping to screen for a cardiac enlargement early so that patients can get treatment as early as possible. PA chest X-ray in addition to easier availability, lower costs and not dependent on operator capabilities are expected to be a reliable examination⁸.

CTR on chest X-ray is the most common method of describing the heart size. The cardiothoracic ratio (CTR) is determined as a means of assessing cardiac size. It is defined as the ratio of the transverse width of the heart (TD) to the width of the thoracic outlet (WD). Cardiomegaly is present when the CTR is greater than 0.5⁸. The cardiac right side (TR) represents the right atrium and the cardiac left side (TL) represents the left ventricle and part of the right ventricle. Based on the anatomy of the cardiac shadow in the PA chest X-ray, we are interested in conducting research by measuring the transversal left cardiothoracic ratio (TL-CTR). The TL-CTR defined as the

ratio of the transverse left of the heart (TL) to the width of the thoracic outlet (WD). The aim of this study was to compare cardiac size with indicator of cardiothoracic ratio and transversal left cardiothoracic ratio in posteroanterior chest x-ray and echocardiography.

2. Methods

This cross-sectional study was carried out on adult patients 20-60 years old attending to Department of Radiology and Cardiac Centre (PJT) Teaching Hospital Makassar, South Sulawesi, Indonesia from January - March 2019. This study was conducted in patients with normal cardiac size and cardiac enlargement. Patients with an abnormal body build, a spinal deformity, a distended abdomen, gross pulmonary disease of emphysematous changes, pulmonary disease with atelectasis and pleural effusion have been excluded. A total of 101 patients and 88 of them met the inclusion criteria. Patient's cardiac size was determined by 2-D echocardiography and PA Chest X-ray. The standard PA CXR was taken on deep inspiration with film exposure at a distance of 6 ft. 88 inclusion samples were divided into three groups. (i) Group with normal cardiac size, (ii) group with left ventricular enlargement, (iii) group with right ventricular enlargement.

2.1 Radiographic measurements

The cardiac size was assessed on PA Chest X-ray. Following measurements were recorded (figure 1):

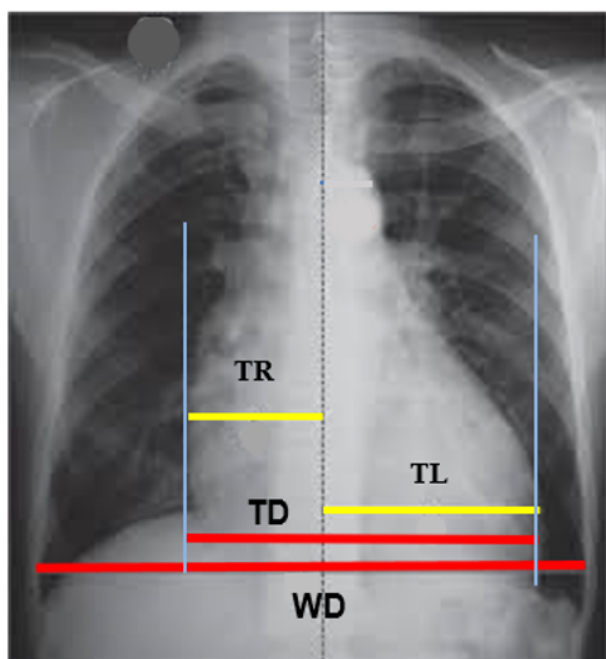


Figure 1. Chest X-ray PA View: Determine of the cardiac size. TL: Transversal Left, TR: Transversal Right, TD: Transversal diameter, WD: Widest diameter.

- (i) Transverse left (TL): Left side of a central perpendicular line
- (ii) Transverse right (TR): Right side of a central perpendicular line
- (iii) Transverse diameter (TD): the widest diameter of the cardiac silhouette. $TD = TL + TR$
- (iv) Widest diameter (WD): -the widest diameter of chest, taken a distance between the internal surface of the ribs on the right and left sides
- (v) Cardio-thoracic ratio (CTR) = $TD/WD \times 100$ (normal = 50% or less)
- (vi) Transverse left Cardio-thoracic ratio (TL-CTR): $TL/WD \times 100$ (normal = 50% or less)

2.2 Echocardiographic measurements

Echocardiography measurements were made on 2D mode and M-mode PLAX (parasternal long axis) positions in the end diastolic phase. The transducer was placed in the left fourth intercostal space in the ultrasonic beam, the dimension of both the ventricles were recorded.

Following measurements were recorded (Figure 2):

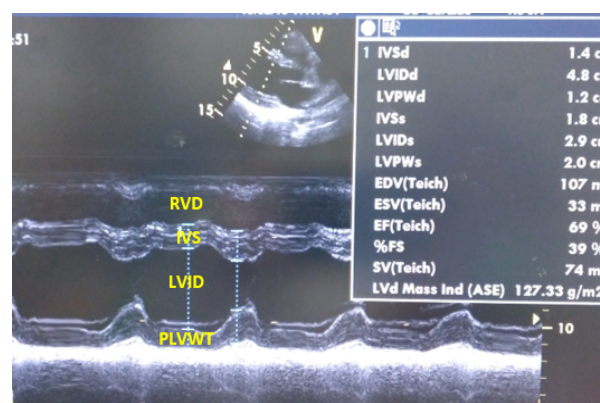


Figure 2. M-mode echocardiogram from group normal cardiac size. Measurement, LVID: Left ventricular internal dimension, PLVWT: Posterior left ventricular wall thickness, IVS: interventricular septum, RVD: Right ventricular dimension, TVD: Total ventricular dimension.

- (i) Right ventricular dimension (RVD)
- (ii) Left ventricular internal dimension (LVID)
- (iii) Posterior left ventricular wall thickness (PLVWT),
- (iv) Interventricular septal wall (IVS)
- (v) Total ventricular dimension (TVD) = $RVD + LVID + PLVWT + IVS$

3. Results

The study involved 88 inclusion samples, 48 male (55.2%) and 40 female (44.8%). 36.36% samples 20-30 year of age, 11.40% 31-40 years of age, 18.18% 41-50 years of age, 34.09% 51-60 years of age. Based on cardiac size divided into three groups. (i) Group with normal cardiac size, it was found in 38 subjects (43.7%) (ii) Group with left ventricular enlargement (LVE), 47 subjects (54.7%). dan (iii) Group with right ventricular enlargement (RVE), 3 subjects (2.3%). The distribution of cases shows in table 1.

Observation as recorded from the result of CXR and echocardiography examination and their comparison are as follows. Group normal cardiac size: table 2 shows minimum, maximum, mean and standard deviation value on PA chest X-ray and echocardiography in group normal cardiac size.

Table 3 shows that there is no correlation between TVD on echocardiography with CTR ($p = 0.187$), TL-CTR ($p = 0.557$), TL ($p = 0.320$) and TD ($p = 0.329$) on PA CXR in group normal cardiac size.

Groups left ventricular enlargement: table 4 shows minimum, maximum mean and standard deviation value on PA chest X-ray and echocardiography in group left ventricular enlargement. Table 5 shows very strong positive correlation between TVD on echocardiography with CTR ($p < 0,0001$), TL-CTR ($p < 0,0001$), TL ($p < 0,0001$) and TD ($p < 0,0001$) on PA CXR in groups left ventricular enlargement, however the CTR has a slightly better correlation than TL-CTR and TD has slightly better correlation than TL. LVID on echocardiography shows very strong positive correlation with CTR, TL-CTR, TL and TD (each $p < 0.0001$) on PA CXR, however CTR has a slightly better correlation than TL-CTR and TD has a better correlation than TL.

Groups right ventricular enlargement: table 6 shows that there is no correlation between TVD and RVD on echocardiography shows with CTR, TL-CTR, TL, TD on PA CXR in groups right ventricular enlargement.

Tabel 1. The distribution of cases (n=88)

Demographic	n	%
Gender		
Male	48	55,2
Female	40	44,8
Age (year)		
20-30	32	36,36
31-40	10	11,36
41-50	16	18,18
51-60	30	34,09
Group		
Normal cardiac size	38	43,18
Left ventricular enlargement	47	53,40
Right ventricular enlargement	3	3,40

Table 2. Minimum, maximum, Mean and standard deviation value on PA chest X-ray and echocardiography in group normal cardiac size

PA Chest X-ray			Echocardiography		
Variable	Min-Max	Mean \pm SD	Variable	Min-Max	Mean \pm SD
1. TL (cm)	4.9-9.0	7.3 \pm 1.04	1. RVD (cm)	0.8-2.2	1.5 \pm 0.4
2. TR (cm)	3.1-5.5	4.2 \pm 0.55	2. LVID(cm)	3.2-4.8	4.1 \pm 0.4
3. TD (cm)	8.9-13.0	11.5 \pm 1.02	3. PLVWT(cm)	0.7-1.8	0.9 \pm 0.2
4. WD (cm)	22.0-33.0	26.8 \pm 2.91	4. IVS (cm)	0.7-1.2	0.9 \pm 0.1
5. CTR (%)	34.8-46.8	43.4 \pm 4.01	5. TVD (cm)	6.1-8.9	7.3 \pm 0.7
6. TL-CTR (%)	21.4-33.7	27.4 \pm 3.23			

SD: Standard Deviation, TL: Transversal Left, TR: Transversal Right, TD: Transversal diameter, WD: Widest diameter, CTR: Cardiothoracic Ratio, TL-CTR: Transverse left Cardiothoracic Ratio, LVID: left ventricular internal dimension,

PLVWT: Posterior left ventricular wall thickness, IVS: Interventricular septum, RVD: Right ventricular dimension, TVD: Total ventricular dimension

Table 3. Spearman's correlation variable on PA chest X-ray and echocardiography group normal cardiac size

	CTR		TL-CTR		TL		TD	
	p	r	p	r	p	r	p	r
TVD	0.187	-0.219	0.557	-0.098	0.557	-0.098	0.320	0.166

CTR: Cardiothoracic Ratio, TL-CTR: Transverse left Cardiothoracic Ratio, TL: Transversal Left, TD: Transversal diameter, LVID: left ventricular internal dimension, TVD: Total ventricular dimension

Table 4. Minimum, maximum, Mean and standard deviation on PA chest X-ray and echocardiography group left ventricular enlargement

Variable	PA Chest X-ray		Variable	Echocardiography	
	Min-Max	Mean ±SD		Min-Max	Mean± SD
1. TL (cm)	7.214-21	11.1±1.7	1. RVD (cm)	0.9-3.3	1.7±0.6
2. TR (cm)	3.4-9.0	5.8±1.3	2. LVID(cm)	4.1-8.1	5.9±1.0
3. TD (cm)	11.8-22.7	16.9±2.7	3. PLVWT(cm)	0.8-1.6	1.1±0.2
4. WD (cm)	21.7-32.2	27.02±2.6	4. IVS (cm)	0.5-2.0	1.1±0.3
5. CTR (%)	50.4-80.8	62.5±8.1	5. TVD (cm)	7.7-13.8	9.9±0.3
6. TL-CTR (%)	32.4-50.8	41.1±5.2			

SD: Standard Deviation, TL: Transversal Left, TR: Transversal Right, TD: Transversal diameter, WD: Widest diameter, LVID: left ventricular internal dimension, PLVWT: Posterior left ventricular wall thickness, IVS: Interventricular septum, RVD: Right ventricular dimension, TVD: Total ventricular dimension

Table 5. Pearsons correlation variable on PA chest X-ray and echocardiography group left ventricular enlargement

	CTR		TL-CTR		TL		TD	
	p	r	p	r	p	r	P	r
TVD	<0.0001	0.672	<0.0001	0.610	<0.0001	0.644	<0.0001	0.693
LVID	<0.0001	0.680	<0.0001	0.566	<0.0001	0.681	<0.0001	0.767

CTR: Cardiothoracic Ratio, TL-CTR: Transverse left Cardiothoracic Ratio, TL: Transversal Left, TD: Transversal diameter, LVID: left ventricular internal dimension, TVD: Total ventricular dimension

Table 6. Pearsons correlation variable on PA chest X-ray and echocardiography group right ventricular enlargement

	CTR		TL-CTR		TL		TD	
	p	r	p	r	p	r	p	r
TVD	0.569	-0.627	0.642	-0,526	0.785	-0.332	0.852	-0.526
RVD	0.473	0.736	0.552	0.647	0.689	0.469	0.373	0.757

CTR: Cardiothoracic Ratio, TL-CTR: Transverse left Cardiothoracic Ratio, TL: Transversal Left, TD: Transversal diameter, LVID: left ventricular internal dimension, TVD: Total ventricular dimension, RVD: Right ventricular dimension

4. Discussion

In groups normal, it does not show correlation between TVD on echocardiography with CTR, TL-CTR, TL and TD on PA CXR. This is different from the results of the study reported by Sinha U et al (2013), where in the normal group it was reported that there was a strong correlation between TVD and TL and a weak positive correlation between TVD and CTR and TD. In groups left ventricular enlargement, shows a very strong positive correlation between TVD and LVID on echocardiography with CTR, TL- CTR, TL and TD on PA CXR. The possible reason is that the left ventricular space forms the lower left part of the heart shadow. Therefore any dilatation of the left ventricular cavity will always manifest in the form of enlarged heart shadow, shows that any abnormal increase in cardiac size will be reflected in the PA chest X-ray. Sinha U et al (2013) reported, TVD shows a strong positive correlation with CTR, but LVID shows a poor correlation with CTR and TL[9]. In groups right ventricular enlargement, there was not correlation between TVD and RVD on echocardiography with CTR, TL- CTR, TL and TD on PA CXR.

5. Conclusion

- The cardiothoracic ratio (CTR) and transverse left-cardio-thoracic ratio (TL-CTR) on PA chest X-ray are very good indicators for the total ventricular dimension (TVD) and left ventricular internal dimension (LVID) on echocardiography, however CTR has a slightly better correlation than TL-CTR.
- The cardiothoracic ratio (CTR), transverse left-cardio-thoracic ratio (TL-CTR), transverse left (TL), transverse diameter (TD) on PA chest X-ray are poor indicators for right ventricular dimension (RVD) on echocardiography.
- Transverse diameter (TD) and transverse left (TL) on PA chest X-ray are good

indicators for total ventricular dimension (TVD) and left ventricular internal dimension (LVID) on echocardiography, however TD has a better correlation than TL.

References

1. Park K. Text book of preventive and medicine 20th edn. Madhya Pradesh, Indian Banarsidas Bhanot; 2009. p. 323-6.
2. Satou GM., Lacro RV, Chung T, et al. Heart size on chest x-ray as a predictor of cardiac enlargement by echocardiography in children. *Pediatr Cardiol*; 2001. 22: 218-22
3. Kadhum AAH, Sharif S, Hazaa MA. Validity of chest X-ray in estimation of cardiac size in comparison echocardiography. *Med J Bashrah Univ*. 2007. 25: 48-51.
4. Anderson B. Basic Principles of M-Mode. Echocardiography: The normal examination and echocardiographic measurements. First edition. MGA graphics: Queensland; 2002.
5. Lange, S. Radiology of chest disease. Third edition. Germany. Thieme; 2007. p.262-264.
6. Nkomo VT, Gardin JM, Skeleton TN. Burden of valvular heart disease: a population based study. *Lancet*. 368: 1005-1011
7. Dinsmore RE. Chest roentgenography. In: principles and practice of cardiovascular imaging pohost GM, O'Rourke RA, eds. Little, Brown: Boston; 2002.
8. Matthias, H. The Chest X-ray : A Systemic Teaching Atlas. Germany. Thieme; 2007, p.20,27,81
9. Sinha, U., Sahay, U.S., Athavale, Deopujari, R., Kumar, S. 7 January 2013. Comparative Study of Cardiac Size by Chest X-ray and Echocardiography. *Journal of The Anatomical Society of India*. 62: 28-3