

DISTRIBUTION OF REGULATORY T CELLS OF TUMOR MICROENVIRONMENT OF EXTRANODAL NK/T CELL LYMPHOMA, NASAL TYPE IN YOUNG PATIENTS

Krisna Murti*¹, Eriza², Esti Fitria Hatami¹, Sandria¹, Nora Ramkita¹, Iche Andriyani Liberty³

¹Department of Anatomic Pathology Faculty of Medicine Sriwijaya University/Dr. Mohammad Hoesin Hospital Palembang

²Department of Ear Nose and Throat Faculty of Medicine Sriwijaya University/Dr. Mohammad Hoesin Hospital Palembang

³Department of Public Health and Community Medicine Faculty of Medicine Sriwijaya University Palembang

krisna.arinafril@unsri.ac.id

ABSTRACT

Extranodal NK/T-cell lymphoma, nasal type (ENKTCL-NT), is a malignancy derived from NK or T-cell lines, characterized by vascular damage, extensive necrosis, a cytotoxic phenotype, and association with Epstein-Barr virus (EBV). This aggressive tumor presents severe clinical symptoms and is marked by high morbidity and mortality rates. Despite a well-understood pathogenesis, the mortality rate remains high. The tumor microenvironment (TME) plays a crucial role in the disease's pathogenesis and progression, with Treg cells expressing anti-FOXP3 markers being a significant component. This observational study, utilizing a case series design, was conducted with a total sample of 16 paraffin blocks from NKTCL-NT patients registered at Dr. Mohammad Hoesin General Hospital (RSMH) Palembang, from January 2018 to December 31, 2023, who met the inclusion and exclusion criteria. Anti-FOXP3 antibody was applied to all samples. Patients with ENKTCL-NT were predominantly male (68.75%), while females constituted 31.25%. The age range of the subjects was 14-40 years, with the majority (62.5%) falling within the third to fourth decades of life. The most common anemia status observed was moderate anemia (46.15%), followed by mild anemia (38.46%). The early stage of the disease was the most frequent (66.67%). The population of subjects with high and low FOXP3 expression was equally distributed at 50% each. Subjects with a high density of FOXP3-expressing cells were more commonly found in patients with early-stage disease and those with mild to moderate anemia status.

Keywords : *ENKTCL, Nasal Type, Treg, FOXP3, young ages*

1. INTRODUCTION

Extranodal NK/T-cell lymphoma, nasal type (ENKTCL-NT), is a malignancy originating from extranodal immune cells, specifically derived from natural killer (NK) or T-cell lines. This type of lymphoma is characterized by notable vascular damage, extensive tissue necrosis, and a cytotoxic phenotype that often exhibits angiocentric and angiodestructive features.¹ A significant association has been established between this lymphoma and Epstein-Barr virus (EBV), which can be reliably detected through Epstein-Barr encoding region in-situ hybridization (EBER-ISH) examination.² Approximately 80% of ENKTCL-NT cases occur in the nasal cavity, paranasal sinuses, or upper aerodigestive tract.³

This type of lymphoma (ENKTCL-NT), is prevalent among Eastern Asian and central and southern Native American populations, accounting for approximately 5% to 15% of newly diagnosed lymphoma cases.³ However, it is also observed in individuals of white ethnic backgrounds in Western countries.⁴ The disease predominantly affects adults, with a median age range of 35 to 58 years and exhibits a higher incidence in male patients.⁵ Extranodal NK/T-cell lymphoma, nasal type typically presents with severe clinical manifestations, and in many cases, it can progress to a more aggressive form of lymphoma. Consequently, the morbidity and mortality rates associated with this malignancy are significantly high.

The tumor microenvironment (TME) plays a crucial role in the pathogenesis and progression of this disease. One significant

component of the TME that contributes to the disease's development and advancement is the presence of T lymphocytes. Among these lymphocytes, regulatory T cells (Tregs) constitute a subpopulation that suppresses the immune response to maintain homeostasis and self-tolerance. Tregs are essential for preventing the excessive proliferation of T cells and cytokines, thereby playing a critical role in the prevention of autoimmunity. These cells are identified by the presence of FOXP3 markers, which can be detected through immunohistochemical examination.

The prognosis of ENKTCL-NT, is influenced by multiple factors, including the disease stage, the patient's age, the histopathological type, and the patient's survival status, which can be assessed by examining overall survival (OS) and disease-free survival (DFS) in other patients. Accurate staging of the disease in patients with ENKTCL-NT is critical for selecting

appropriate initial treatment, which subsequently affects the patient's recovery.

The staging system for ENKTCL-NT is based on the Ann Arbor staging system (AASS), initially developed for Hodgkin lymphoma.⁶This AASS-based staging system, which is widely utilized in Indonesia, takes into account factors such as the location of the tumor and/or lymphadenopathy involvement, the number and size of tumors/lymph nodes, the presence of adjacent extranodal lymph node involvement, systemic spread of the disease, and the presence of B symptoms (see Table 1). Clinicians at Dr. Mohammad Hoesin General Hospital (RSMH), both the ENT and Internal Medicine departments employ the AASS, which consists of four stages. According to this classification, the majority of ENKTCL-NT patients (70-90%) present with early-stage disease (stages I/II) at diagnosis, whereas advanced-stage disease (stages III/IV) is relatively uncommon.

Table 1. ENKTCL-NT staging based on Ann Arbor staging system⁶

Staging	Involvement
I	A single region of lymph nodes or a single site outside the limited (extranodal) lymphatic system.
II	Two or more groups of lymph nodes on the same side of the diaphragm.
III	Lymph nodes on both sides of the diaphragm, lymph nodes above the diaphragm with splenic involvement.
IV	Non-adjacent extralymphatic involvement (e.g. lung, liver or bone metastases). For all stages A. No symptoms B. Any B symptom (below) is eligible: - Fever: Unexplained fever, temperature >38°C. - Night sweats: sweating until drenched. - Unexplained weight loss >10% over the past 6 months. X. Bulky tumour >10 cm in diameter or mediastinal mass E. Adjacent extranodal involvement

Almost all malignant tumors, including ENKTCL-NT, possess a TME characterized by heterogeneous populations encompassing a variety of elements surrounding the cancer cells. These variations include differences in morphology, phenotype, and biological function. The heterogeneous nature of the TME is influenced by multiple factors,

including genetic mutations, epigenetic changes, interactions with the microenvironment, and metabolic processes. The interaction between the tumor and its surrounding environment, known as the tumor microenvironment, comprises regulatory T cells, macrophages, extracellular matrix components, lymphocytes, immune

checkpoints, and other elements. Several factors play pivotal roles in either the progression or potential cure of cancer, including immune and cell cycle regulators, the presence of cancer stem cells, and modulation of the tumor microenvironment.⁷ A significant component of the TME is a subset of T cells with regulatory functions, including FOXP3 positive Tregs that exhibit abnormal functions.⁸ Regulatory T cells are a subpopulation of T cells that suppress the immune response to maintain homeostasis and self-tolerance. Furthermore, Tregs can inhibit the proliferation of T cells and cytokines, playing a crucial role in preventing autoimmunity. In some cases of malignant tumors, an increase in positive FOXP3 Tregs has been observed in the blood of patients with active disease compared to healthy controls. Notably, after the disease enters remission, the number of Tregs in the blood returns to normal levels. This dynamic behavior of Tregs highlights their importance in the pathogenesis and potential therapeutic targeting of malignancies such as ENKTCL-NT.⁹

In cases of lymphoma, Tregs present a distinctive profile, which allows for their classification into four distinct groups.¹⁰ This classification provides significant insights into the TME due to the interactions between Tregs and other cellular components. Furthermore, this classification is instrumental in predicting disease prognosis and is invaluable for devising therapeutic strategies for lymphomas based on Treg-targeted immunotherapies. For instance, in lymphoma patients with infiltration of Treg cells classified as either suppressor Tregs or malignant Tregs, the function of these cells in suppressing anti-tumor cytotoxicity is diminished. This reduction in Treg cell numbers is typically associated with a favorable prognosis. Conversely, in lymphoma patients with a TME infiltrated by tumor-killing Tregs and incompetent Tregs, the anti-tumor cytotoxicity is enhanced, or the anti-autoimmune activity of Tregs is weakened. In these cases, an increase in the

number of Tregs is linked to a favorable prognosis, while a decrease in Treg numbers is associated with a poor prognosis.¹⁰ This nuanced understanding of Treg cell behavior and classification in lymphoma cases underscores the importance of Tregs in the pathogenesis, prognosis, and treatment of the disease. It highlights the potential for Treg-based immunotherapies to significantly impact therapeutic outcomes, offering a targeted approach to improving patient prognoses and tailoring individualized treatment plans.

Although it is documented in the literature that ENKTCL-NT exhibits infiltration by Treg cells,^{11,12} there remains a paucity of comprehensive studies elucidating the functional significance of Treg cells in this context. Furthermore, no Treg cell types have been identified as prognostic or predictive markers, nor have they been proposed as therapeutic candidates for patients with ENKTCL-NT. Consequently, our hypothesis posits that Treg cells potentially play a pivotal role in the progression of ENKTCL-NT. This investigation aims to assess the expression of FOXP3 protein within the TME of ENKTCL-NT patients who are under the care at Dr. Moh. Hoesin Hospital Palembang.

2. METHOD

This study employed an observational design with a descriptive approach utilizing paraffin block samples obtained from patients registered at the Department of Anatomic Pathology of the Faculty of Medicine, Sriwijaya University/RSUP Dr. Moh. Hoesin Palembang, spanning the period from 1 January 2018 to 31 December 2023. Clinical data, including treatment details and patient follow-up information, were partially sourced from the medical records of Dr. Moh. Hoesin Hospital Palembang. The research was conducted at the Department of Anatomic Pathology / Dr. Moh. Hoesin Hospital Palembang. The study population encompassed all patients whose paraffin block archives and medical records met the predefined inclusion criteria during the aforementioned period at the Department of

Anatomic Pathology Faculty of Medicine University of Sriwijaya / RS. Dr. Moh. Hoesin Palembang.

The sampling technique employed in this study was consecutive sampling, which involved the systematic selection of participants based on predefined inclusion criteria. These criteria included: 1) Histopathologically diagnosed NKTCL-NT cases confirmed by surgery and biopsy results at the the Department of Anatomic Pathology of the Faculty of Medicine, Sriwijaya University/RSUP Dr. Moh. Hoesin (RSMH) Palembang from 1 January 2018 to 31 December 2023, with archival records of HE preparations. 2) Availability of clinicopathological data pertaining to NKTCL-NT, such as tumor size, location, and primary or secondary tumor status, documented in the medical records of the Department of Anatomic Pathology of the Faculty of Medicine, Sriwijaya University / RSMH Palembang during the same period. 3) Paraffin block archives of NKTCL-NT specimens in optimal condition, containing sufficient tumor mass for potential recutting in case of damage to HE preparations and ensuring adequacy for immunohistochemical analysis. 4) Complete medical records including immunohistochemical examination results of NKTCL-NT cases from surgical and/or biopsy procedures conducted at Department Anatomic Pathology Faculty of Medicine, Sriwijaya University / RSMH Palembang, as well as records from the medical record installation of RSMH Palembang spanning 1 January 2017 to 31 December 2023. 5). The availability of archived immunohistochemical preparations of NKTCL-NT derived from surgeries and/or biopsies performed at Department Anatomic Pathology Faculty of Medicine, Sriwijaya University (FK UNSRI) / RSMH Palembang during the period from 1 January 2017 to 31 December 2023. 6) Complete medical records containing stage data and laboratory findings from the Medical Record Installation of RSMH Palembang between 1 January 2018 and 31 December 2023. Exclusion criteria encompassed cases where histopathological

images of NKTCL-NT HE preparations exhibited signs of degeneration or cellular damage attributed to inadequate fixation procedures.

Immunohistochemistry Staining

Paraffin blocks of ENKTCL-NT subject tissues, which included inclusion in the Department of Anatomic Pathology Installation of Dr. Moh. Hoesin Hospital Palembang, were meticulously sectioned to a thickness of 4 micrometres for subsequent immunohistochemical analysis. The process commenced with deparaffinisation and rehydration of the tissue through sequential immersion in xylene for two periods of 10 minutes each. This was followed by immersion in absolute ethanol for two periods of 5 minutes each, then in 90% ethanol for 1 minute, 80% ethanol for 1 minute, and 70% ethanol for 1 minute. Subsequently, internal peroxidase activity was blocked by immersing the tissue preparation in a 0.3% hydrogen peroxide solution for 15 minutes, after which it was thoroughly washed with distilled water and PBS three times for 5 minutes each. Antigen retrieval was achieved by heating the tissue in Tris-EDTA HIER Solution (10x) at pH 9, initially at a high power level for 5 minutes followed by a low power level for 15 minutes. The tissue was then allowed to cool to room temperature and washed with PBS three times for 5 minutes each.

To prevent non-specific binding, UltraTek Super Block was applied and incubated for 5 minutes at room temperature, thereby minimizing non-specific background staining. The preparation was subsequently rinsed with 10X Tris-Buffered Saline (TBS) stock for 5 minutes and incubated with an anti-FOXP3 primary antibody at a dilution of 1:100, left to incubate overnight. Following this, the tissue was washed three times with TBS 10X for 5 minutes each. The tissue was then treated with Biotinylated link antibody, incubated for 10 minutes, washed with PBS three times for 5 minutes each, and incubated with streptavidin peroxidase for 10 minutes, followed by another wash with PBS three times for 5 minutes each. The chromogenic

staining was performed using DAB chromogen (1:50 in substrate) with an incubation period of 15 minutes, after which the preparation was rinsed with distilled water. The background of the preparation was stained with Hematoxylin for 15-30 seconds, followed by a wash with running tap water for 5 minutes. The slide was then dehydrated through a graded series of alcohols and cleared by immersing it in xylene three times for 3 minutes each. Finally, the slide was mounted with a mounting medium and covered with a cover glass.

Data processing

The study utilized both primary and secondary data sources. The secondary data comprised the evaluation results of Hematoxylin and Eosin (HE) and Immunohistochemical (IHC) slides, alongside sociodemographic and clinical data of patients diagnosed with ENKTCL-NT, collected during the period from January 1, 2018, to December 31, 2023. These data were

retrieved from the Anatomical Pathology Installation and the Department Medical Records of RSMH Palembang. Primary data consisted of the evaluation results of the IHC examination slides that were stained using anti-FOXP3 antibody. All data collected for the research were precisely verified manually and subsequently recorded in the research database. Descriptive data evaluation and analysis were conducted on the collated data.

3. RESULT

After the selection process of inclusion and exclusion criteria, a total of 16 samples were obtained that met the inclusion criteria. These 16 samples corresponded to ENKTCL-NT patients registered at RSMH Palembang, all of whom were aged 40 years or younger. The cohort was predominantly male, with 11 out of the 16 patients (68.75%) being male. The age range of the patients in this study was between 14 and 40 years, with a median age of 32 years (Table 1).

Table 1. Characteristics of ENKTCL patients, Nasal type

No	Gender	Ages (years)	Anemia	Staging	Foxp3
1	M	23	Mild	Early (I)	High
2	F	14	Mild	Early(I)	Low
3	M	40	Life threatening	Early (I)	Low
4	M	38	Normal	Early (I)	Low
5	M	22	Mild	Advanced (IV)	Low
6	F	22	Moderate	Early (I)	High
7	F	37	Moderate	Advanced (IV)	High
8	M	38	Mild	Advanced (IV)	N/A
9	M	28	Moderate	N/A	High
10	M	33	Moderate	Early (IE)	High
11	M	38	Moderate	Early (I)	High
12	F	32	N/A	N/A	High
13	F	24	Mild	Advanced (IV)	Low
14	M	32	Moderate	Early (I)	Low
15	M	34	N/A	N/A	N/A
16	M	32	Severe	N/A	Low

In this study, data of haemoglobin were available for only 14 samples. Among these, 5 patients (38.46%) were found to have mild anaemia, while 6 patients (46.15%) exhibited moderate anaemia. Severe and life-

threatening anaemia were each observed in 1 patient (7.7%). Additionally, 1 patient (7.7%) showed no signs of anaemia (Tables 1 and 2).

Out of the 16 samples, stage data were available for only 12 samples. Based on the

Ann Arbor staging system, the stages represented in this study included stage I, IE, and IV. Specifically, stage I was identified in 7 samples, and stage IE in 1 sample, resulting in a total of 8 samples (66.67%) classified as stage I overall. Stage IV was observed in 4 samples (34.33%) (see Tables 1 and 2).

After quantifying the FOXP3-embedded Treg cells (Figure 1), a skewness/kurtosis test was conducted to assess the distribution of

FOXP3⁺ Treg cells. The distribution was found to be abnormal. Consequently, the median value of 5.95 was utilized as a cutoff point to classify the FOXP3-overexpressing cells into high-density and low-density categories. The results indicated that the proportion of samples with high density was 50%, while the proportion with low density was also 50% (Tables 1 and 2).

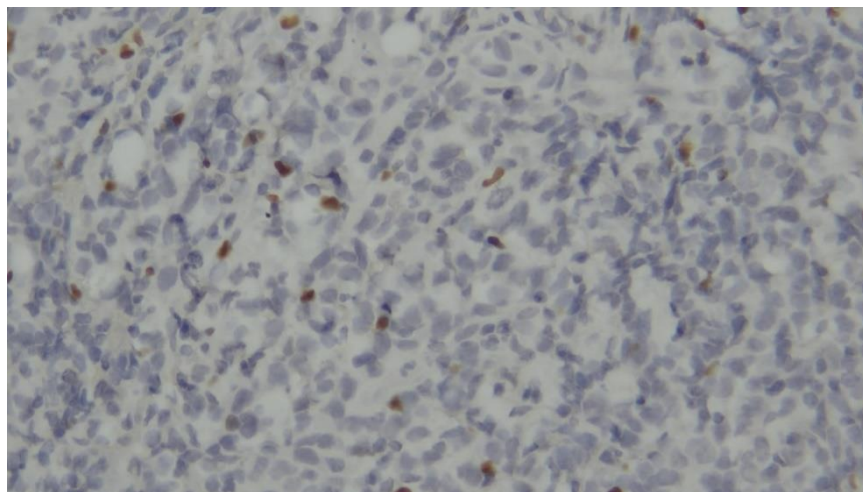


Figure1. FOXP3⁺ expression on lymphocyte cells. It can be seen that the lymphocytes in between the tumour cells expresses positive FOXP3 (brown colour in the nucleus of the lymphocyst cells).

Table 2. Characteristics of ENKTCL patients, Nasal type

Characteristic	Total	Percentage (%)
Age (years)		
• <20	• 1	• 6.25
• 21-30	• 5	• 31.25
• 31-40	• 10	• 62.5
Gender		
• Male	• 11	• 68.75
• Female	• 5	• 31.25
Anemia		
• Mild	• 5	• 38.46
• Moderate	• 6	• 46.15
• Severe	• 1	• 7.7
• Life threatening	• 1	• 7.7
Clinical staging		
• I (Including IE)	• 8	• 66.67
• II	• 0	• 0
• III	• 0	• 0
• IV	• 4	• 34.33
Distribution of Tregs (FOXP3 ⁺)		
• High	• 7	• 50
• Low	• 7	• 50

4. DISCUSSION

Among the patients with ENKTCL-NT aged 40 years and younger registered at Dr. Moh. Hoesin Hospital, Palembang (Tables 1 and 2), a total of 16 individuals were identified. This cohort was predominantly male, with 11 males' patients comprising 68.42% of the total. This finding aligns with data from various studies,^{13,14} which indicate that the incidence of ENKTCL-NT is higher among males. This gender disparity may be attributable to the greater risk factors encountered by men, such as smoking, occupational hazards, exposure to pollution, stress, and sexual contact, which increase susceptibility to Epstein-Barr Virus (EBV) infection. EBV is recognized as one of the etiological factors in the development of ENKTCL-NT.¹⁵

The age range of patients in this study was from 14 to 40 years, with a median age of 32 years. Specifically, among the 16 samples, the youngest patient was 14 years old (representing 6.25% of the cohort). Five patients (31.25%) were aged between 21 and 30 years, while the majority, 10 patients (62.5%), were aged between 31 and 40 years. The highest incidence of ENKTCL-NT lymphoma generally occurs in the fourth and fifth decades of life.¹⁶ However, in developed countries, the incidence of ENKTCL-NT cases tends to be higher among older populations, with a median age of 53 years.¹⁷ This discrepancy may be attributed to the higher incidence of Epstein-Barr Virus (EBV) infection among younger individuals in Asian countries.

Transmission of EBV is facilitated in environments with poor sanitary conditions and high population density, factors prevalent in developing countries like Indonesia.¹⁸ Studies indicate that EBV can also spread through sexual contact, which is more frequent among younger individuals compared to older age groups.¹⁹

Registered ENKTCL-NT lymphoma patients had anaemia status in 13 out of 14 samples (92.85%). One subject with normal Hb value (Table 1) based on anaemia grading according to the National Cancer

Institution.²⁰ Laboratory data was unavailable for 2 samples. The anaemia observed in this study cohort included severe anaemia in one patient, life-threatening anaemia in another, moderate anaemia in 6 samples (the most prevalent type), and mild anaemia in 5 patients. It is noteworthy that severe or life-threatening anaemia can manifest early in the disease course, while even advanced disease may present with only mild anaemia. Hence, anaemia status alone may not suffice to predict the prognosis of ENKTCL-NT patients, necessitating consideration of additional contributing factors.

Subjects exhibiting positive FOXP3 expression were identified in 14 out of 16 samples (87.5%). Two subjects were excluded due to extensive tissue necrosis and minimal tumour cell presence. The FOXP3 protein serves as the most specific marker for identification and plays a pivotal role in immune suppression mechanisms.²¹ The present study observed a comparable distribution between high and low density Tregs, with 48.28% classified as high density and 51.72% as low density. A notable trend emerged wherein samples with high FOXP3 expression tended to correlate with patients in early disease stages and displaying mild to moderate anaemia (Table 1 and 2). This association aligns with findings suggesting early stage disease and favorable prognosis, as demonstrated in previous studies. Nonetheless, it remains plausible that FOXP3 expression levels may fluctuate over the course of the disease progression.¹² Importantly, FOXP3 positive Treg cells were analyzed in tumor tissues obtained from patients prior to any therapeutic intervention in this study.

5. CONCLUSION

Patients diagnosed with ENKTCL, NT exhibited a notable predominance of males and were predominantly aged in their third to fourth decades. Among these patients, moderate anaemia was identified as the most frequent anaemia status, and early stage disease was the most prevalent stage observed. Furthermore, individuals

demonstrating a high density of FOXP3-expressing cells tended to be more prevalent among patients with early stage disease and mild to moderate anaemia status.

REFERENCE

1. Wang H, Li P, Zhang X, Xia Z, Lu Y, Huang H. Histological vascular invasion is a novel prognostic indicator in extranodal natural killer/T-cell lymphoma, nasal type. *Oncol Lett.* 2016;12(2):825-836. doi: 10.3892/ol.2016.4691. Epub 2016 Jun 9. PMID: 27446357; PMCID: PMC4950690.
2. Wai CMM, Chen S, Phyu T, Fan S, Leong SM, Zheng W, Low LCY, Choo SN, Lee CK, Chung TH, Ban KHK, Ghosh S, Lie S, Kato S, Nakamura S, Takahashi E, Ko YH, Khoury JD, Chuang SS, Au-Yeung RKH, Tan SY, Lim ST, Ong CK, Ho YH, Poon LM, De Mel S, Jeyasekharan AD, Chng WJ, Otto F, Quintanilla-Martinez L, Zanardi F, Iannelli F, Tripodo C, Pitt JJ, Ng SB. Immune pathway upregulation and lower genomic instability distinguish EBV-positive nodal T/NK-cell lymphoma from ENKTL and PTCL-NOS. *Haematologica.* 2022;107(8):1864-1879. doi: 10.3324/haematol.2021.280003. PMID: 35021606; PMCID: PMC9335103.
3. Tse E., Kwong YL. The diagnosis and management of NK/T-cell lymphomas. *J Hematol Oncol* 2017;10, 85. <https://doi.org/10.1186/s13045-017-0452-9>
4. Vargo JA, Patel A, Glaser SM, Balasubramani GK, Farah RJ, Marks SM, et al. The impact of the omission or inadequate dosing of radiotherapy in extranodal natural killer T-cell lymphoma, nasal type, in the United States. *Cancer.* 2017;123(16):3176–85
5. de Mel S, Hue SSS, Jeyasekharan AD, Chng WJ & Ng SB. Journal of Molecular pathogenic pathways in extranodal NK/T cell lymphoma. *Hematol Oncol.*2019;12(33).
6. Carbone PP, Kaplan HS, Musshoff K, Smithers DW, Tubiana M. "Report of the Committee on Hodgkin's Disease Staging Classification". *Cancer Res.* 1971.31(11): 1860–1861.
7. Nayak A, Warriar NM, Kumar P. Cancer Stem Cells and the Tumor Microenvironment: Targeting the Critical Crosstalk through Nanocarrier Systems. *Stem Cell Rev Rep.* 2022 ;18(7):2209-2233. doi: 10.1007/s12015-022-10426-9. Epub 2022. PMID: 35876959; PMCID: PMC9489588.
8. Mitchell JM, Berzins SP, Kannourakis G. A potentially important role for T cells and regulatory T cells in Langerhans cell histiocytosis, *Clin Immunol.* 2018.194:19-25. ISSN 1521-6616, <https://doi.org/10.1016/j.clim.2018.06.004>.
9. Wang H, Lu CH, and Ho PC. Metabolic adaptation orchestrates tissue context-dependent behavior in regulatory T cells. *Immunol Rev.* 2020;295(1):126-139. doi: 10.1111/imr.12844. Epub 2020 Mar 8. PMID: 32147869.
10. Wang J and Ke XY. The Four types of Tregs in malignant lymphomas. *J Hemato Oncol.* 2011,4:50. <http://www.jhoonline.org/content/4/1/50>
11. Kim WY, Jeon YK, Kim TM, Kim JE, Kim YA, Lee SH, Kim DW, Heo DS & Kim CW. Increased quantity of tumor-infiltrating FOXP3-positive regulatory T cells is an independent predictor for improved clinical outcome in extranodal NK/T-cell lymphoma. *Annals Oncol.*2009;20:1688–1696. doi:10.1093/annonc/mdp056
12. Cho YJ, Kim SJ, Park WY, Kim J, Woo J, Kim G, Yoon SE, Ko YH, Kim

- WS. Immune subtyping of extranodal NK/T-cell lymphoma: a new biomarker and an immune shift during disease progression. *Mod Pathol.*2020;33(4):603-615. doi: 10.1038/s41379-019-0392-8.
13. Chan JK, Quintanilla-Martinez L, Ferry JA, et al: Extranodal NK/T-cell lymphoma, nasal type. In: Swerdlow SH, Campo E, Harris NL, Jaffe ES, Pileri SA, Stein H, Thiele J and Vardiman JW (eds). WHO classification of tumours of haematopoietic and lymphoid tissues. Lyon, France, IARC Press, pp285-288, 2008.
 14. Chan JKC, Quintanilla-Martinez L and Ferry JA: Extranodal NK/T-cell lymphoma, nasal type. In: Swerdlow SH, Campo E, Harris NL, Jaffe ES, Pileri SA, Stein H and Thiele J (eds). WHO classification of tumours of haematopoietic and lymphoid tissues, revised 4th edition. IARC Press, Lyon, pp368-371, 2017.
 15. Montes-Mojarro, I.A.; Fend, F.; Quintanilla-Martinez, L. EBV and the Pathogenesis of NK/T Cell Lymphoma. *Cancers.* 2021;13, 1414. <https://doi.org/10.3390/cancers13061414>.
 16. Takahara M, Kumai T, Kishibe K, Nagato T, Harabuchi Y. Extranodal NK/T-Cell Lymphoma, Nasal Type: Genetic, Biologic, and Clinical Aspects with a Central Focus on Epstein-Barr Virus Relation. *Microorganisms.* 2021;9(7):1381. <https://doi.org/10.3390/microorganisms9071381>
 17. Kommalapati A, Tella SH, Ganti AK, Armitage JO. Natural Killer/T-cell Neoplasms: Analysis of Incidence, Patient Characteristics, and Survival Outcomes in the United States. *Clin Lymphoma Myeloma Leuk.* 2018;18(7):475-479. doi: 10.1016/j.clml.2018.04.009. Epub 2018 May 4. PMID: 29752210.
 18. Alebouyeh M, Peller P, Goetz O, Ameri MA. Comparative study of the prevalence of Epstein-Barr virus infections in Iran and Germany. *Monatsschr Kinderheilkd.* 1984;132(11):850-1
 19. Crawford DH, et al (2002) Swerdlow AJ, Higgins C, McAulay K, Harrison N, Williams H, et al. Sexual history and Epstein-Barr virus infection. *J Infect Dis.* 2002;186(6):731-6.
 20. Madeddu C, Gramignano G, Astara G, Demontis R, Sanna E, Atzeni V, Macciò A. Pathogenesis and Treatment Options of Cancer Related Anemia: Perspective for a Targeted Mechanism-Based Approach. *Front Physiol.* 2018;9:1294. doi: 10.3389/fphys.2018.01294. PMID: 30294279; PMCID: PMC6159745.
 21. Li Z, Li D, Tsun A, Li B. FOXP3+ regulatory T cells and their functional regulation. *Cell Mol Immunol.* 2015;12(5):558-65. doi: 10.1038/cmi.2015.10. Epub 2015 Feb 16. PMID: 25683611; PMCID: PMC4579651.